

Thrombotic microangiopathy-like hemolysis in vitamin B12 deficiency-related megaloblastic macrocytic anemia

B12 vitamini eksikliği ile ilişkili megaloblastik makrositik anemide trombotik mikroanjiopati benzeri hemoliz

Damla Çağla Patır , Lütfiye Bilge Çalışkan , Harun Akar 

Department of Internal Medicine, Health Sciences University, İzmir Tepecik Training and Research Hospital, İzmir, Turkey

ABSTRACT

Vitamin B12 deficiency is common in Turkish population. Depending on the severity of B12 deficiency, patients may present with various clinical conditions and laboratory findings. B12 deficiency may manifest as thrombotic microangiopathy-like hemolysis. B12 deficiency presenting with thrombotic microangiopathy-like hemolysis may be called pseudothrombotic microangiopathy. Pseudothrombotic microangiopathy is anemia, thrombocytopenia, and schistocytosis caused by vitamin B12 deficiency. Pseudothrombotic microangiopathy may be mistakenly confused with microangiopathic hemolytic anemia, which can lead to confusion about the appropriate treatment approaches. Assessment of lactate dehydrogenase, reticulocyte count, bilirubin, and platelet counts may allow pseudothrombotic microangiopathy to be distinguished from a true microangiopathic hemolytic anemia. In this article, we report a case of pseudothrombotic microangiopathy due to severe vitamin B12 deficiency.

Keywords: Hemolytic anemia; thrombocytopenia; Vitamin B12 deficiency.

ÖZ

Türk nüfusunda B12 vitamini eksikliği yaygındır. B12 eksikliğinin ciddiyetine bağlı olarak hastalar çeşitli klinik durumlar ve laboratuvar bulguları ile başvurabilir. B12 eksikliği trombotik mikroanjiopati benzeri hemoliz olarak ortaya çıkabilir. Trombotik mikroanjiopati benzeri hemoliz ile seyreden B12 eksikliği psödotrombotik mikroanjiopati olarak adlandırılabilir. Psödotrombotik mikroanjiopati B12 vitamini eksikliğinin neden olduğu anemi, trombositopeni ve schistocytosisdir. Psödotrombotik mikroanjiopati yanlışlıkla mikroanjiopatik hemolitik anemi ile karıştırılarak uygun tedavi yaklaşımları hakkında karmaşaya yol açabilir. Laktat dehidrogenaz, retikülosit sayımı, bilirubin ve trombosit sayımları değerlendirilerek psödotrombotik mikroanjiopati gerçek bir mikroanjiopatik hemolitik anemiden ayırt edilebilir. Bu yazıda, ciddi B12 vitamini eksikliğinden kaynaklanan bir psödotrombotik mikroanjiopati olgusu bildirildi.

Anahtar sözcükler: Hemolitik anemiler; trombositopeni; Vitamin B12 eksikliği.

The chemical name, “cobalamin” is vitamin B12, an essential water-soluble micro nutrient required by all cells in the body. Humans are unable to synthesize B12 and thus are dependent on nutrient intakes and complex intracellular pathways for vitamin processing and target delivery. Vitamin B12 (cobalamin) is found in

animal meat, particularly red meat. Food-derived cobalamin binds to protein, is separated from protein by mild acid and pepsin, and is bound to haptocorrin in gastric secretions. The cobalamin in the haptocorrin-cobalamin complex is released by the pancreatic proteases. The intrinsic factor is secreted from gastric parietal cells.

Received: May 29, 2018 **Accepted:** July 08, 2018

Correspondence: Damla Çağla Patır, MD. Sağlık Bilimleri Üniversitesi, İzmir Tepecik SUAM, İç Hastalıkları Kliniği, 35180 Yenisehir, Konak, İzmir, Turkey.
Tel: +90 539 - 273 05 92 e-mail: damlapatir@yahoo.com

Atrif:

Patır DÇ, Bilge Çalışkan L, Atabay Y, Akar H. Thrombotic microangiopathy-like hemolysis in vitamin B12 deficiency-related megaloblastic macrocytic anemia. FNG & Bilim Tıp Dergisi 2018;4(3):145-148.

The cobalamin-intrinsic factor complex binds to cubilin+amnionless receptors on the ileum mucosa cells and is introduced into the cell. In the form of transcobalamin, it reaches the portal circulation and then target tissues. In the tissues, adenosylcobalamin and methylcobalamin are converted, which are needed for various chemical reactions. In the presence of anemia and accompanying macrocytosis, vitamin B12 deficiency is suspected. However, full blood count is not the only accepted diagnostic test. When iron deficiency anemia, thalassemia carriage or inflammatory diseases accompany vitamin B12 deficiency, normocytic and even micro values can be seen. Macroscopic oval erythrocytes, anisocytosis, poikilocytosis, schistocytes and young myeloid precursors and hypersegmentation in neutrophils may be seen, particularly in severe deficiencies. Vitamin B12 deficiency may present with hemolytic anemia, thrombocytopenia, and schistocytosis, mimicking a microangiopathic hemolytic anemia. This is known as pseudothrombotic microangiopathy. In this article, we present a case of pseudothrombotic microangiopathy due to severe vitamin B12 deficiency.^[1,2]

CASE REPORT

An 87-year-old male patient presented with fatigue for one year. The patient with a hemoglobin level of 6.8 g/dL was admitted to the internal medicine clinic for

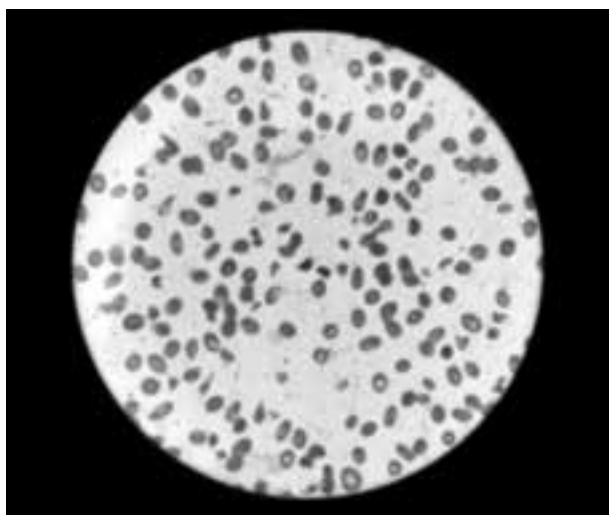


Figure 1. Peripheral smear showing multiple schistocytes.

further examination and treatment. At the first examination, the temperature was 37°C, blood pressure was 125/67 mm/Hg, pulse rate was 82/minute, and respiratory rate was 18/minute. No pathological finding was found on physical examination. Laboratory findings were as follows; white blood cell: 5,100/mm³, hemoglobin: 6.8 gr/dL, platelet: 71,000/mm³, mean corpuscular volume: 115.4 fL, iron: 19 ug/dL, alanine aminotransferase: 25 U/L, aspartate aminotransferase: 84 U/L, alkaline phosphatase: 60 U/L, lactate dehydrogenase (LDH): 1,953 U/L, international normalized ratio: 1.02, activated partial thromboplastin time: 18.7 second, vitamin B12: 88 pg/dL, folic acid: 3.56 ng/mL, total bilirubin: 2.37 mg/dL, direct bilirubin: 0.32 mg/dL, HBsAg(-), AntiHBs(-), AntiHAV IgM(-), AntiHAV IgG(-), AntiHCV(-), AntiHIV(-), Anti-CMV IgM(-), AntiToxo IgM(-), AntiRubella IgM(-), EBV VCA IgM(-), ANA(-), AMA(-), and Anti-SM(-). Indirect and direct coombs were negative and positive, respectively. Patient's peripheral blood smear was compatible with macrocytic anemia, hypersegmented neutrophils and schistocytes (Figure 1). Patient was considered to manifest a clinical picture similar to microangiopathic hemolytic anemia due to severe B12 deficiency. Patient without symptoms of anemia did not receive erythrocyte suspension. He underwent intramuscular B12 replacement. After B12 replacement, his hemoglobin level rose to 8.7 gr/dL. Peripheral blood smear after vitamin B12 replacement did not show schistocytes. Patient was discharged with the recommendation of the outpatient clinic follow-up. A written informed consent was obtained from the patient.

DISCUSSION

Our patient exhibited an uncommon manifestation of vitamin B12 deficiency: pseudothrombotic microangiopathy. The cause of this pseudothrombotic microangiopathy appeared to be intramedullary destruction of erythrocytes (ineffective erythropoiesis). In a case series of 201 patients with vitamin B12 deficiency, 2.5% of patients showed pseudothrombotic microangiopathy.^[3] The rare occurrence of pseudothrombotic microangiopathy makes accurate identification and diagnosis difficult. Since an inappropriate

diagnosis of thrombotic thrombocytopenic purpura (TTP) may lead to a large number of unnecessary and expensive treatments such as intensive care unit admission and plasmapheresis, it is important to distinguish between pseudothrombotic microangiopathy and a true microangiopathic hemolytic anemia such as TTP. When treating a patient with suspected pseudothrombotic microangiopathy, laboratory works are indispensable. Lactate dehydrogenase and bilirubin levels should be assessed. An elevated LDH as well as relatively normal unconjugated bilirubin are suggestive of pseudothrombotic microangiopathy. The mechanism referred to is that the nucleated erythrocytes in the bone marrow elevate the LDH much more when they are lysed than un-nucleated erythrocytes in the peripheral blood. In addition, the immature erythrocytes in the bone marrow contain very little hemoglobin, leading to only minor increases in the unconjugated bilirubin when lysed.^[1-13] Another important laboratory study that suggests pseudothrombotic microangiopathy is a low reticulocyte count. This is expected because of the lack of B12 vitamins leading to defective deoxyribonucleic acid synthesis and the production of megaloblastic cells.

Eighty to ninety percent of these cells are destroyed in the bone marrow through the action of marrow macrophages. This intramedullary hemolysis is the cause of the low reticulocyte count (ineffective erythropoiesis). The platelet count should also be checked. TTP-associated thrombocytopenia is usually severe, with a mean of approximately 12,500 platelets/ μL . The mean platelet count of patients with pseudothrombotic microangiopathy is around 70,000 platelets/ μL .^[1-13] In this case, the platelet count was 71,000 platelets/ μL , typical for pseudothrombotic microangiopathy.

Pseudothrombotic microangiopathy is a clinical picture due to severe B12 deficiency and is characterized by anemia, thrombocytopenia and schistocytosis. The number of platelets in pseudothrombotic microangiopathy is higher than the platelet count in TTP.^[1-13] Assessment of LDH, reticulocyte count, bilirubin and platelet counts is most useful when a pseudothrombotic microangiopathy is distinguished from a true microangiopathic hemolytic anemia.^[3,10]

Declaration of conflicting interests

The authors declared no conflicts of interest with respect to the authorship and/or publication of this article.

Funding

The authors received no financial support for the research and/or authorship of this article.

REFERENCES

1. Watkins D, Whitehead VM, Rosenblatt DS. Megaloblastic anemia. In: Orkin SH, Nathan DG, Ginsburg D, Look AT, Fisher DE, Lux SE, editors. *Nathan and Oski's Hematology of infancy and childhood*. Philadelphia: Saunders Elsevier; 2009. p. 467-520.
2. Green R. Folate, cobalamin, and megaloblastic anemias. In: Kaushansky K, Lichtman MA, Beutler E, Kipps TJ, Seligson U, Prchal JT, editors. *Williams Hematology*. 9th ed. Shanghai: The McGraw-Hill Companies; 2010. p. 533-64.
3. Oh R, Brown DL. Vitamin B12 deficiency. *Am Fam Physician* 2003;67:979-86.
4. Hvas AM, Nexø E. Diagnosis and treatment of vitamin B12 deficiency--an update. *Haematologica*. 2006;91:1506-12.
5. Bor MV, Cetin M, Aytac S, Altay C, Nexø E. Nonradioactive vitamin B12 absorption test evaluated in controls and in patients with inherited malabsorption of vitamin B12. *Clin Chem* 2005;51:2151-5.
6. Bolaman Z, Kadikoylu G, Yukselen V, Yavasoglu I, Barutca S, Senturk T. Oral versus intramuscular cobalamin treatment in megaloblastic anemia: a single-center, prospective, randomized, open-label study. *Clin Ther* 2003;25:3124-34.
7. Carmel R, Green R, Rosenblatt DS, Watkins D. Update on cobalamin, folate, and homocysteine. *Hematology Am Soc Hematol Educ Program* 2003:62-81.
8. Carmel R. How I treat cobalamin (vitamin B12) deficiency. *Blood* 2008;112:2214-21.
9. Hannibal L, Kim J, Brasch NE, Wang S, Rosenblatt DS, Banerjee R, et al. Processing of alkylcobalamins in mammalian cells: A role for the MMACHC (cblC) gene product. *Mol Genet Metab* 2009;97:260-6.
10. Antony AC. Megaloblastic anemias. In: Hoffman R, Benz EJ Jr, Shattil SJ, Furie B, Cohen HJ, Silberstein LE, et al, editors. *Hematology, Basic Principles and Practice*. 4th ed. Philadelphia: Elsevier; 2005. p. 519-56.
11. Andr es E, Affenberger S, Zimmer J, Vinzio S, Grosu D, Pistol G, et al. Current hematological findings in cobalamin deficiency. A study of 201 consecutive patients with documented cobalamin deficiency. *Clin Lab Haematol* 2006;28:50-6.

12. Noël N, Maigné G, Tertian G, Anguel N, Monnet X, Michot JM, et al. Hemolysis and schistocytosis in the emergency department: consider pseudothrombotic microangiopathy related to vitamin B12 deficiency. *QJM* 2013;106:1017-22.
13. Veit K. Pseudothrombotic microangiopathy and vitamin B12 deficiency in pernicious anemia. *Proc (Bayl Univ Med Cent)* 2017;30:346-7.