

## Fat and skin necrosis: A rare adverse event in a child due to *Tetanus and Diphtheria Vaccine*

Ezgi Hasbek<sup>1</sup>, Emine Kübra Dindar Demiray<sup>2</sup>, Sevil Alkan<sup>3</sup>, Metin Hüseyin Metineren<sup>4</sup>

<sup>1</sup>Department of Pediatrics Clinic, Bitlis State Hospital, Bitlis, Türkiye

<sup>2</sup>Department of Infectious Disease, Bitlis State Hospital, Bitlis, Türkiye

<sup>3</sup>Department of Infectious Disease, Çanakkale Onsekiz Mart University, Çanakkale, Türkiye

<sup>4</sup>Department of Pathology, Kütahya Health Sciences University, Evliya Çelebi Hospital, Kütahya, Türkiye

### ABSTRACT

Vaccines are the most economical and effective method applied to protect the health of society and the individual. The extended vaccination program and our national immunization calendar in the eighth grade diphtheria-tetanus (DT & Td) vaccine adult-type are also used in this context. Tetanus immunization is administered in the form of adult DT & Td after the age of 7-10 years. Since diphtheria toxoid is less in amount, it has fewer side effects compared to diphtheria, tetanus, and pertussis (DTaP & Tdap) and DT & Td vaccines at this age. However, local skin infection is observed in one out of every four people following vaccination applications, but there may be rare cases that progress to severe soft tissue infections. With this case, we reported a rare case of DT & Td vaccination-associated deep wound infection in the skin and subcutaneous tissues that was admitted to a pediatric outpatient clinic.

**Keywords:** Childhood, local side effects, subcutaneous tissue infection, DT & Td vaccine, DTaP & Tdap.

Tetanus is an infectious disease caused by the bacteria called *Clostridium tetani* that can be prevented by vaccination and causes mortality and morbidity worldwide.<sup>[1]</sup>

Vaccines are the most effective and safe method for protecting the health of individuals and communities, preventing the spread and complications of infectious diseases, and achieving sustainable health-based gains in countries.<sup>[2]</sup> Since 2009, Turkey has also implemented an “Expanded Immunization Program”, and with successful vaccination programs, neonatal tetanus, which causes high mortality in Turkish children, has been eradicated. As part of this program, the last dose of diphtheria-tetanus

(DT & Td) vaccine for the childhood age group is administered to 8<sup>th</sup>-grade students. In addition to children, these vaccines are provided free of charge to people of all ages in family medicine centers.

Following vaccinations, both systemic (fever, rash, headache, behavioral changes) and local (pain, redness, swelling) symptoms can develop.<sup>[3]</sup> Local side effects, also known as Arthus reaction or hypersensitivity reaction, occur especially after the administration of DT & Td vaccines. This is usually due to a high antibody response following toxoid administration.<sup>[4]</sup> However, tetanus immunization is administered as adult tetanus toxoid after 7-10 years of age, and it is known that it has fewer side effects than diphtheria, tetanus, and pertussis (DTaP & Tdap) and DT & Td vaccines at these ages due to containing less diphtheria toxoid. According to the Centers for Disease Control and Prevention (CDC), most children do not experience any side effects after receiving DTaP & Tdap. Mild side effects such as redness, swelling, or pain at the injection site, fever, or vomiting may occur.<sup>[1]</sup>

Received: April 08, 2021

Accepted: May 04, 2021

Published online: May 24, 2023

Correspondence: Emine Kübra Dindar Demiray

E-mail: e.kubradindar@hotmail.com

### Cite this article as:

Hasbek E, Dindar Demiray EK, Alkan S, Metineren MH. Fat and skin necrosis: A rare adverse event in a child due to *Tetanus and Diphtheria Vaccine*. D J Med Sci 2023;9(1):19-23. doi: 10.5606/fng.btd.2023.34.

In this article, we present a 14-year-old male patient who developed a local deep skin infection as a side effect of the DT & Td vaccine administered to the left arm deltoid region.

### CASE REPORT

A 14-year-old male patient was admitted to the pediatric outpatient clinic with complaints of swelling, redness, and discharge on his left arm. In his history, it was learned that the DT & Td vaccine was administered within the scope of the immunization program three weeks ago, and a serous discharge wound that disrupted the skin integrity two weeks later in the vaccinated area on the left arm. The patient's vaccinations were administered in accordance with the childhood immunization program, he had no previous allergic reactions, and it was learned that there were no similar local or systemic side effects in classmates who participated in the same vaccination practice. A written informed consent was obtained from the patient.

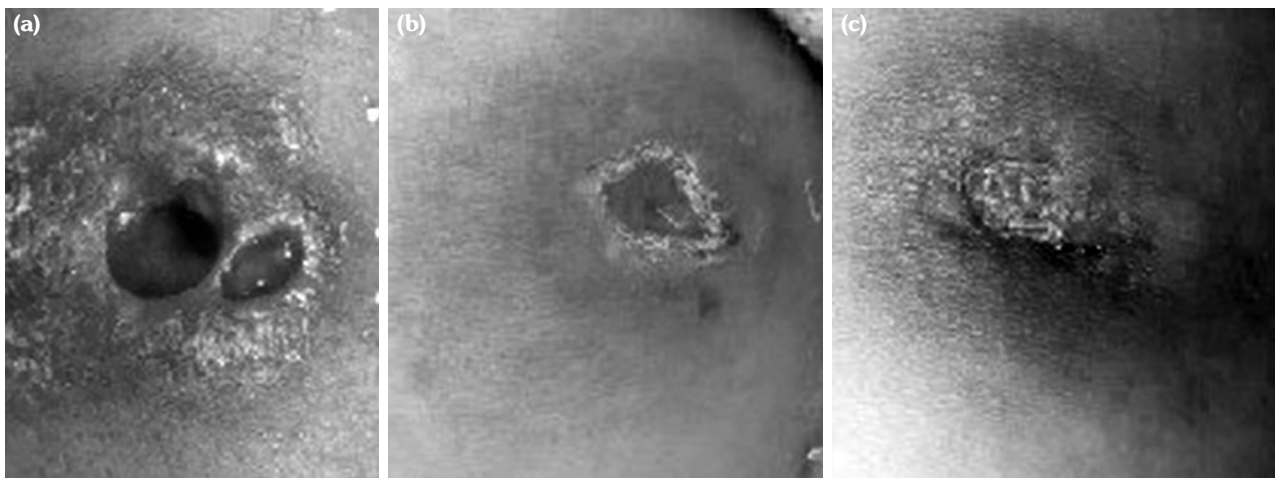
His general condition was good on physical examination; he was conscious, his body temperature was 36.6°C, his pulse was 120/min, and his arterial blood pressure was 110/60 mmHg. In the area corresponding to the deltoid part of the left arm, there were erythema 3×3 cm in diameter, two in the middle, a superficial diameter of 0.5×0.5 cm, and a depth of 1.5 cm, extending to the skin and subcutaneous tissue (Figure 1a). Other system

examinations of the patient were normal. In laboratory tests, hemoglobin was 14.3 g/dL, hematocrit 42.6%, leukocyte count 7,230/mm<sup>3</sup>, MCV 86 fL, platelet count 335,000/mm<sup>3</sup> and CRP 1.2 mg/L (negative). Blood glucose levels, serum electrolytes, liver, and kidney function tests were all within normal ranges. There was no growth in the culture taken from the wound site of the patient who had not previously used antibiotics.

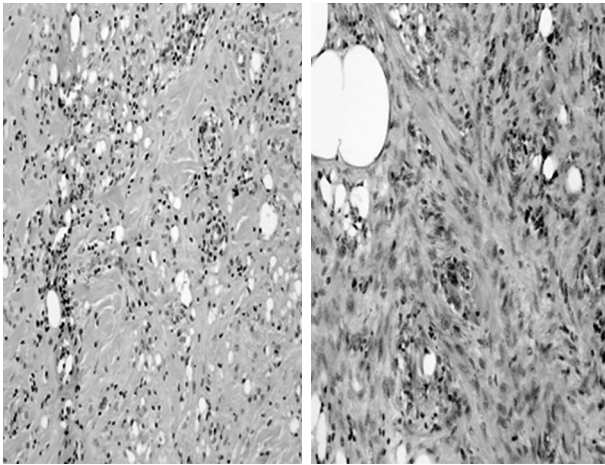
When the patient's medical history and physical examination findings were considered, it was thought that the patient had undesirable local side effects as a result of DT & Td vaccination.

The patient was hospitalized. A tissue biopsy was performed. In addition to a daily wound dressing, intravenous ampicillin-sulbactam at a dose of 100 mg/kg/day and oral ibuprofen suspension at a dose of 10 mg/kg were initiated. Due to the adverse effects of the vaccines, the patient was reported to the relevant Post-Vaccine Adverse Effects unit of the Provincial Health Directorate. Tissue biopsy was positive for fat necrosis and the patient was diagnosed with fat necrosis due to DT & Td vaccination (Figure 2).

After 10 days of intravenous antibiotic therapy, the patient's wound site showed significant improvement, and he was discharged with the recommendation of outpatient clinic control (Figure 1b).



**Figure 1.** (a) Image of the wound at the time of the patient's first hospital admission. (b) Photo of the wound on the 10<sup>th</sup> day of treatment. (c) Photo of the wound at the end of treatment.



**Figure 2.** Microscopic (histologic) description: Histiocytes show relatively uniform in size with round nuclei, fine intracytoplasmic vacuoles and no indentation of the nucleus areas based on time from injury. Intermediate stage: Mixed inflammatory cell (H-E,  $\times 100$ ).

During the physical examination of the patient, who was given 60 mg/kg/day oral amoxicillin-clavulanic acid maintenance therapy for another week, a significant improvement in the wound site was found (Figure 1c).

## DISCUSSION

Tetanus-diphtheria vaccine is a toxoid vaccine administered intramuscularly. Each 0.5 mL single-dose contains diphtheria toxoid 6 Lf/mL ( $>8$  IU) and tetanus toxoid 20 Lf/mL ( $>40$  IU). After the vaccine injection, a few millimeters of papule usually occur and disappears within 30 minutes. This local reaction in the skin has been reported to occur in 90-95% of vaccines. Vaccine-related local skin reactions have generally been reported due to Bacille Calmette-Guérin (BCG) vaccine, and local swelling, redness, discharge occurs in the application area within the first week after vaccination. However, allergic reactions have been reported rarely, both after DT & Td and after DTaP & Tdap. These side effects emerge as fever, restlessness, anorexia, and local reaction (pain, redness, swelling), especially within the first 24 hours of vaccine administration.<sup>[5]</sup>

According to 2017 data, the immunization rate against DTaP & Tdap was 98% in Turkey, 92% in Europe, and 91% in the United

States.<sup>[1]</sup> Children's tetanus vaccination practices in Turkey are carried out at the months of two, four, six, and 18 months, with four doses of 0.5 mL given intramuscularly. The DT & Td vaccine is then administered as a booster to school-age children between the ages of 11 and 12.<sup>[6]</sup> The National Institutes of Health (NIH) conducted a study on 1,015 children who were vaccinated with DTaP & Tdap, and only 2% of the children complained of swelling within the first 48 hours. It has been reported that fever in these patients is not prolonged and high, and the complaint of swelling regressed on the 4<sup>th</sup> day.<sup>[7-9]</sup> According to another study, most of the adverse effects associated with DT & Td vaccination may be due to frequent DTaP & Tdap vaccine doses, young age, female gender, the amount of DT & Td toxoids, and the high immunoglobulin E response generated against these toxoids.<sup>[10,11]</sup>

Haber et al.<sup>[12]</sup> conducted a study in which evaluated the CDC's Vaccine Adverse Event Reporting System (VAERS) for tetanus in people over the age of 65 between 2010 and 2018. In this study there were a total of 1,798 reports of side effects following DTaP & Tdap; 104 (6%) of them were serious. The most common side effects were erythema at the injection site ( $n=468$ , 26%), pain at the injection site ( $n=335$ , 19%), swelling ( $n=329$ , 18%), and were other than injection site ( $n=321$ , 18%). Seven deaths were reported, but none of them were directly related to DTaP & Tdap. The most common of the neurological side effects were infections ( $n=34$ , 35.1%) and infestations ( $n=18$ , 18.6%).

Martin Arias et al.<sup>[13]</sup> conducted a study in the Spanish Pharmacovigilance System database (FEDRA) to investigate the side effects of vaccines. In this study, they reported 45 cases of bursitis and other shoulder injuries that occurred after intramuscular injection of the vaccine into the deltoid muscle. All of the patients were adults, with a median age of 53.6 years (range, 22 to 89) and a majority of women (71.1%) (range, 22 to 89%). The most frequently reported vaccine side effects are influenza and pneumococcus, followed by DTaP & Tdap, DT & Td toxoid, human papillomavirus, and hepatitis A vaccines, and bursitis is the most common shoulder lesion. Most of the patients needed medical care due to severe local pain

and limitation of arm motion. In most cases, symptoms started 48 hours after vaccination.

In the medical literature of local adverse reactions reported as due to vaccines are allergic reactions to vaccine adjuvants, vaccine administration errors, inappropriate needle size, and inappropriate needle length.<sup>[14,15]</sup> Hypersensitivity to aluminum salts following vaccine administration may result in adverse reactions such as delayed erythema, sterile abscess, and subcutaneous nodules.<sup>[16]</sup> There have been reports of skin lesions induced by aluminum salts in the vaccine in the literature.<sup>[17-21]</sup>

In our case, three weeks after the DT & Td injection, there were two wound areas, each around 5×5 mm in diameter, in the middle of an erythematous swelling approximately 3×3 cm in diameter, localized to the area, and 1.5 cm deep into the subcutaneous tissues where the vaccine was administered. There was no accompanying organ involvement, fever, or lymphadenopathy. Because of the depth of the wound and its reach into the subcutaneous tissue, dressing and intravenous ampicillin-sulbactam treatment were started.

Our patient's lesion, which was being closely monitored clinically, regressed rapidly in one week and significantly improved after three weeks. In our patient, the absence of growth in the culture taken was interpreted as allergic skin reaction and fat necrosis due to aluminum in the foreground.

In conclusion, the reported case was who developed a local skin lesion due to the DT & Td vaccine, and no similar case from our country could be found in the literature. The presented case is a rare one, and its diagnosis and treatment are mentioned in the light of the available literature. Although adverse effects related to the DT & Td vaccine are rare, it should be kept in mind that the DT & Td vaccine with reduced toxoid dose may cause local deep skin infections in patients who are completely healthy, have completed their childhood vaccinations, and have previously received DTaP & Tdap vaccine.

#### **Declaration of conflicting interests**

The authors declared no conflicts of interest with respect to the authorship and/or publication of this article.

#### **Funding**

The authors received no financial support for the research and/or authorship of this article.

#### **REFERENCES**

1. Available at: <https://www.cdc.gov/vaccines/parents/diseases/tetanus.html> [Accessed: July 29, 2020].
2. Arısoy ES, Çiftçi E, Hacımustafaoğlu M, Kara A, Kuyucu N, Somer A, et al. Clinical practical recommendations for Turkish national vaccination schedule for previously healthy children (National Vaccination Schedule) and vaccines not included in the schedule - 2015. *J Pediatr Inf* 2015;9:1-11.
3. Turnbull FM, Heath TC, Jalaludin BB, Burgess MA, Ramalho AC. A randomized trial of two acellular pertussis vaccines (dTpa and pa) and a licensed diphtheria-tetanus vaccine (Td) in adults. *Vaccine* 2000;19:628-36.
4. Fritsche PJ, Helbling A, Ballmer-Weber BK. Vaccine hypersensitivity--update and overview. *Swiss Med Wkly* 2010;140:238-46.
5. Decker MD, Edwards KM, Steinhoff MC, Rennels MB, Pichichero ME, Englund JA, et al. Comparison of 13 acellular pertussis vaccines: Adverse reactions. *Pediatrics* 1995;96:557-66.
6. Turkish Republic, Ministry of Health general directorate of health information systems. *Health Statistics Yearbook 2017 Newsletter*; 2018. [Accessed: July 29, 2020].
7. Broder KR, Cortese MM, Iskander JK, Kretsinger K, Slade BA, Brown KH, et al. Preventing tetanus, diphtheria, and pertussis among adolescents: Use of tetanus toxoid, reduced diphtheria toxoid and acellular pertussis vaccines recommendations of the Advisory Committee on Immunization Practices (ACIP). *MMWR Recomm Rep* 2006;55:1-34.
8. Pichichero ME, Deloria MA, Rennels MB, Anderson EL, Edwards KM, Decker MD, et al. A safety and immunogenicity comparison of 12 acellular pertussis vaccines and one whole-cell pertussis vaccine given as a fourth dose in 15- to 20-month-old children. *Pediatrics* 1997;100:772-88.
9. Rennels MB, Deloria MA, Pichichero ME, Losonsky GA, Englund JA, Meade BD, et al. Extensive swelling after booster doses of acellular pertussis-tetanus-diphtheria vaccines. *Pediatrics* 2000;105:e12.
10. Someya S, Mizuhara H, Murata R, Kurokawa M. Studies on the adequate composition of diphtheria and tetanus toxoids-with reference to the amounts of toxoids and aluminum adjuvant. *Jpn J Med Sci Biol* 1981;34:21-35.
11. Mark A, Björkstén B, Granström M. Immunoglobulin E responses to diphtheria and tetanus toxoids after booster with aluminium-adsorbed and fluid DT-vaccines. *Vaccine* 1995;13:669-73.
12. Haber P, Moro PL, Ng C, Dores GM, Perez-Vilar S, Marquez PL, et al. Safety review of tetanus

- toxoid, reduced diphtheria toxoid, acellular pertussis vaccines (Tdap) in adults aged  $\geq 65$  years, Vaccine Adverse Event reporting System (VAERS), United States, September 2010-December 2018. *Vaccine* 2020;38:1476-80.
13. Martín Arias LH, Sanz Fadrique R, Sáinz Gil M, Salgueiro-Vazquez ME. Risk of bursitis and other injuries and dysfunctions of the shoulder following vaccinations. *Vaccine* 2017;35:4870-6.
  14. Batista-Duharte A, Lindblad EB, Oviedo-Orta E. Progress in understanding adjuvant immunotoxicity mechanisms. *Toxicol Lett* 2011;203:97-105.
  15. Zuckerman JN. The importance of injecting vaccines into muscle. Different patients need different needle sizes. *BMJ* 2000;321:1237-8.
  16. Donaldson S, Canavan T, Pavlidakey PG, Cantrell WC, Elewski BE. Injection site necrosis and ulceration following vaccination in an adult patient. *J Drugs Dermatol* 2018;17:364-7.
  17. Alsuwaidi AR, Albawardi A, Khan NH, Souid AK. A 4-month-old baby presenting with dermal necrotizing granulomatous giant cell reaction at the injection site of 13-valent pneumococcal conjugate vaccine: A case report. *J Med Case Rep* 2014;8:285.
  18. Chong H, Brady K, Metze D, Calonje E. Persistent nodules at injection sites (aluminium granuloma) -- clinicopathological study of 14 cases with a diverse range of histological reaction patterns. *Histopathology* 2006;48:182-8.
  19. Lauren CT, Belsito DV, Morel KD, LaRussa P. Case report of subcutaneous nodules and sterile abscesses due to delayed type hypersensitivity to aluminum-containing vaccines. *Pediatrics* 2016;138:e20141690.
  20. Bergfors E, Trollfors B. Sixty-four children with persistent itching nodules and contact allergy to aluminium after vaccination with aluminium-adsorbed vaccines-prognosis and outcome after booster vaccination. *Eur J Pediatr* 2013;172:171-7.
  21. Lehman HK, Faden HS, Fang YV, Ballow M. A case of recurrent sterile abscesses following vaccination: Delayed hypersensitivity to aluminum. *J Pediatr* 2008;152:133-5.